



Letters to the Editor

The use of a toothbrush to debride facial wounds

Sir,

In our unit we use a toothbrush to toilet facial wounds, and would like to recommend this method to your readers.

In severely contaminated facial wounds it is essential to perform thorough debridement so that tattooing does not result. Some areas, particularly the alar margins and inner canthi, are particularly difficult to toilet adequately with the scrubbing brush that is conventionally used in these wounds. We have found that a toothbrush can be used to debride these difficult areas with better precision and less trauma to surrounding tissue (see figure).

In our unit we use a polypropylene brush (Wisdom Regular) which is autoclavable. Some brushes, particularly the clear plastic varieties, do not tolerate autoclaving and should be disinfected with formaldehyde. Advice should be sought from the manufacturer as to the optimum method of disinfecting a particular brush.

We have used toothbrushes in this unit regularly for some time and have found them useful and convenient in the management of this sometimes awkward problem.

Yours faithfully,

P. A. Arnstein, FRCS

Senior Registrar in Plastic Surgery,

A. M. Richards, FRCS

Senior House Officer,

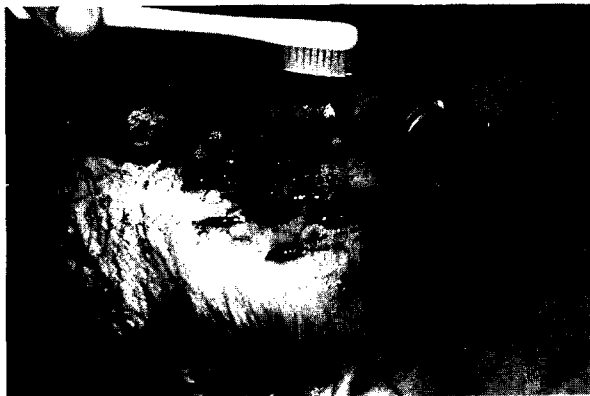Department of Plastic and Reconstructive Surgery,

Queen Victoria Hospital,

Holtye Road,

East Grinstead,

Sussex RH19 3DS



Figure

Figure—The brush in use.

Thromboembolic prophylaxis

Sir,

We have read with great interest both the paper by Dujon *et al.*¹ and the correspondence which followed its publication^{2,3}, and would like to add our support for an increased awareness of the need for thromboembolic prophylaxis in plastic surgery.

We introduced a unit policy for thromboembolic prophylaxis in March 1992 following the publication of a number of articles on this subject⁵⁻⁶. This policy has now been in operation for 12 months, and during this period, 1 patient (0.02% of admissions) has suffered a radiologically proven DVT, and 3 patients (0.07% of admissions) have suffered a pulmonary embolus in the postoperative period. Interestingly, all these patients were provided with compression stockings and low dose subcutaneous heparin for the duration of their hospital admission, in accordance with the policy.

Over the same period, 3 patients (0.07% of admissions) suffered postoperative bleeding or haematoma formation which required a second surgical procedure, while being treated with prophylactic subcutaneous heparin.

We would like to commend the use of written policies for venous thromboembolism prophylaxis, and wondered whether other units might find our algorithm useful (see Figure).

Yours faithfully,

P. J. Drew, FRCS

SHO in Plastic Surgery,

K. Hancock, FRCS

Senior Registrar in Plastic Surgery,

West Midlands Regional Plastic and Jaw Surgery Unit,

Wordsley Hospital,

Wordsley,

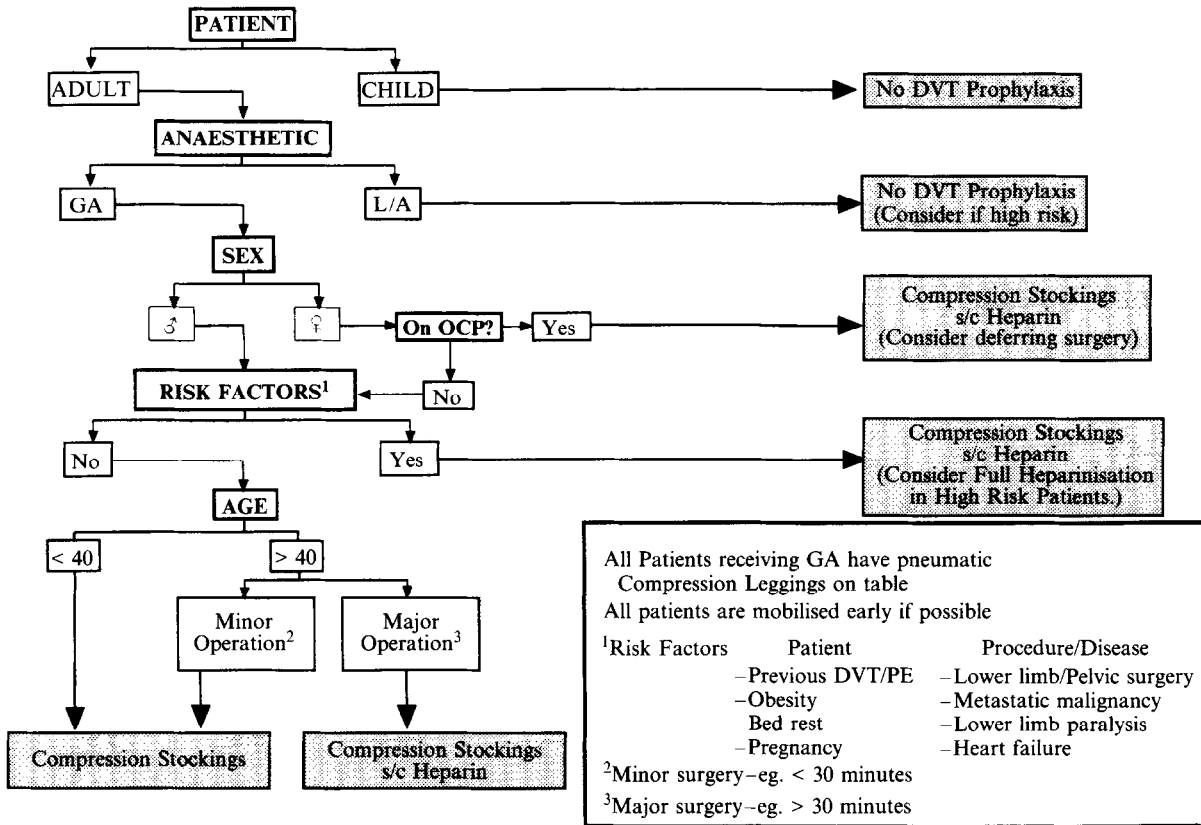
Stourbridge,

West Midlands, DY8 5QX

References

1. Dujon DJ, Chatzis LA, Hart NB. Thromboembolic prophylaxis in plastic surgery: an appraisal. *Br J Plast Surg* 1992; 45: 418-20.
2. Carver N, Ghosh MM, Green AR. Thromboembolic prophylaxis in plastic surgery (letter). *Br J Plast Surg* 1993; 46: 175.
3. Dujon D, Chatzis L, Hart NB. Thromboembolic prophylaxis in plastic surgery—reply (letter). *Br J Plast Surg* 1993; 46: 175.
4. Preventing and treating Deep Vein Thrombosis. (Editorial). *Drug & Therapeutics Bulletin* 1992; 30.
5. Hopkins NFG, Wolfe JHN. Thrombosis and pulmonary embolism. *BMJ* 1991; 303: 1260-2.
6. Laverick MD, Croal SA, Mollan RAB. Orthopaedic surgeons and thromboprophylaxis. *BMJ* 1991; 303: 549-50.

West Midlands Plastic & Jaw Surgery Unit: Policy for Venous Thromboembolism Prophylaxis



Figure